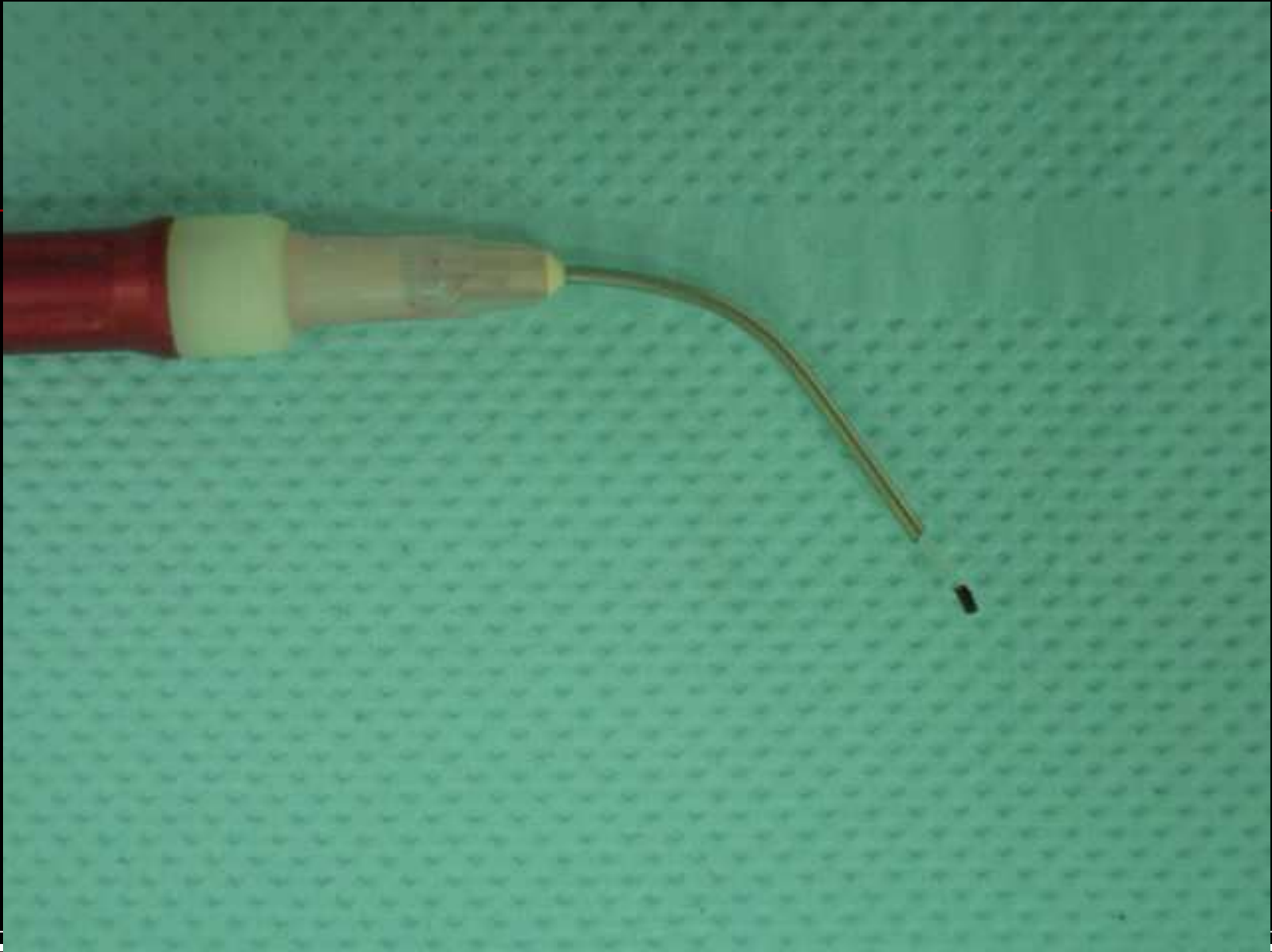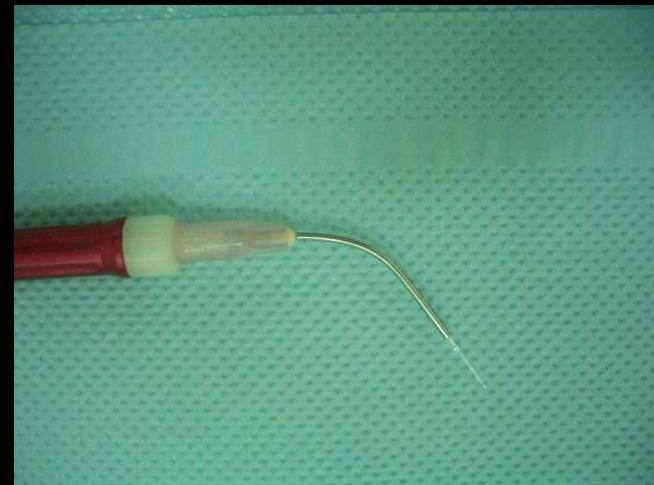
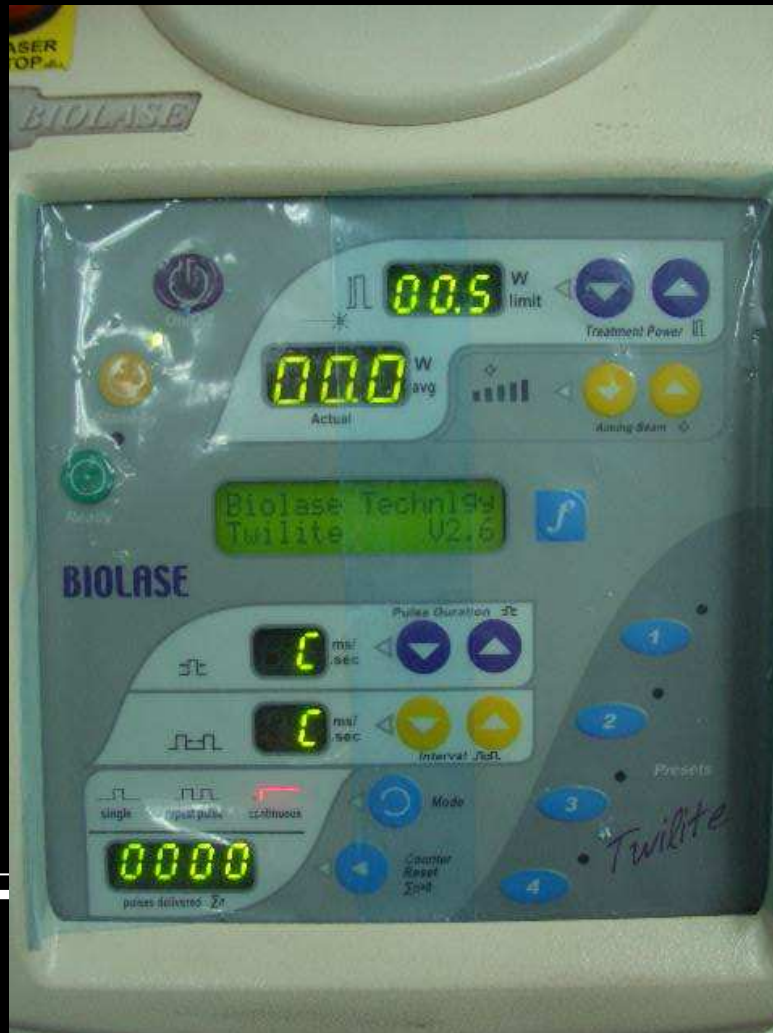


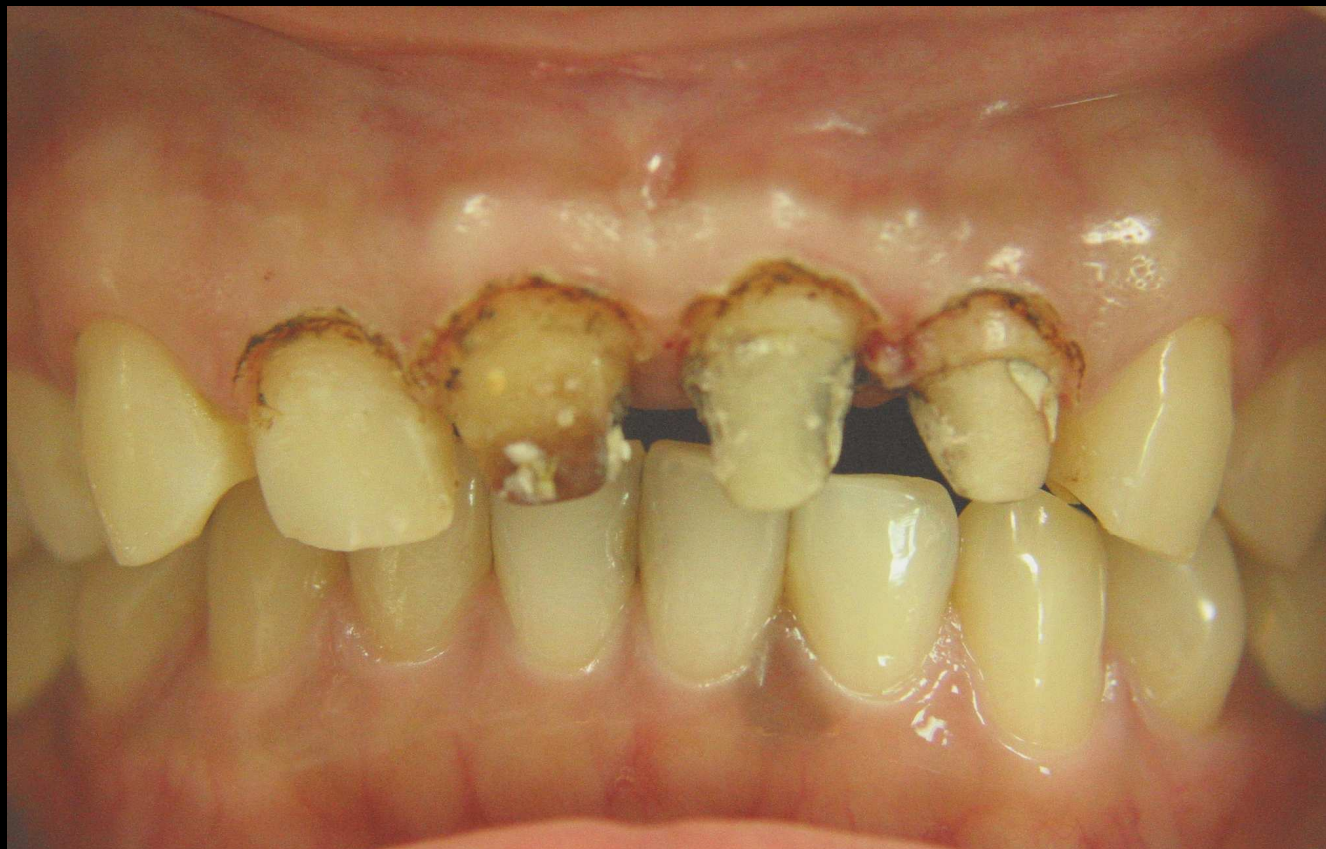# Pocket decontamination

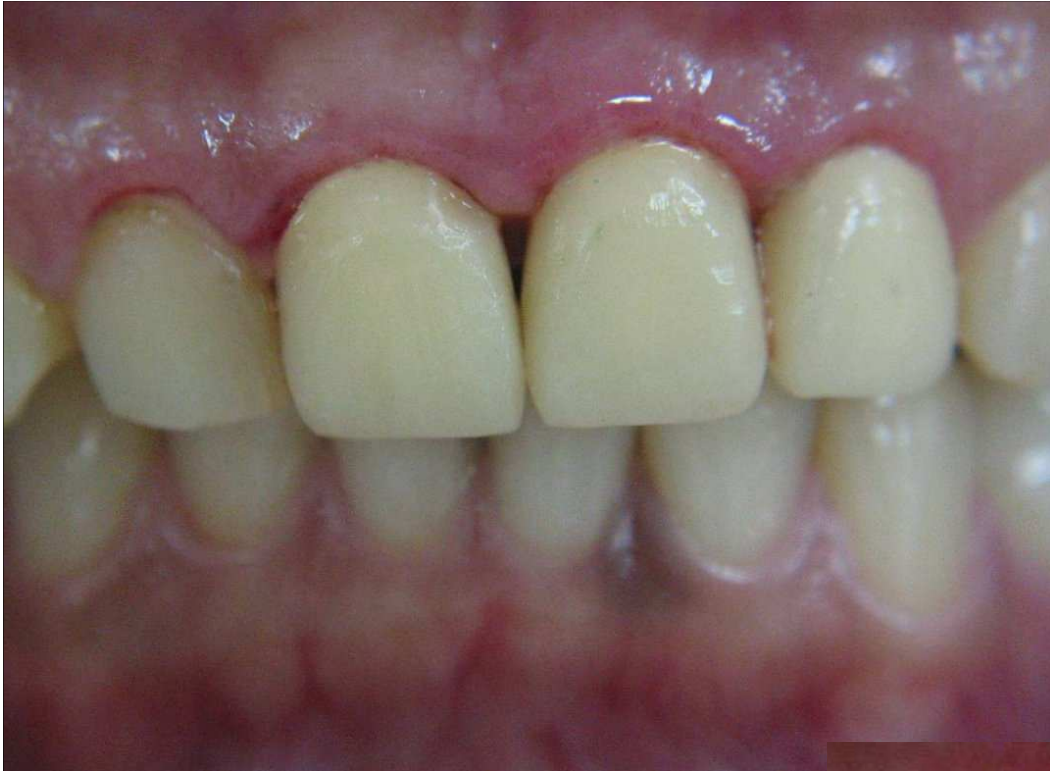

# Immediate post-op

---

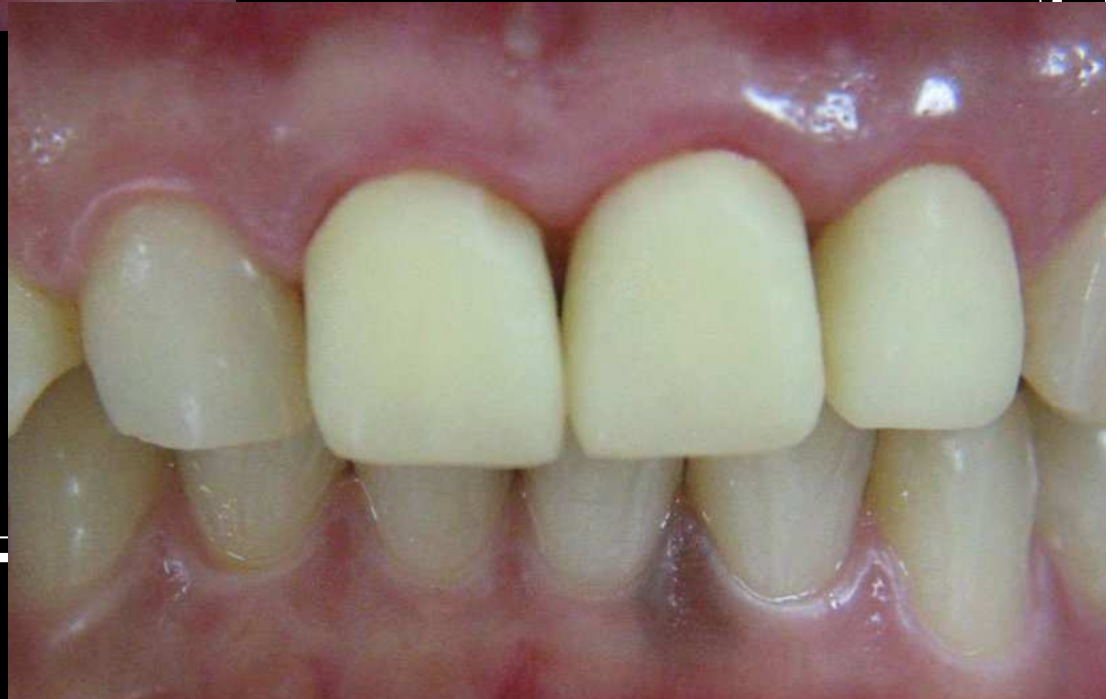


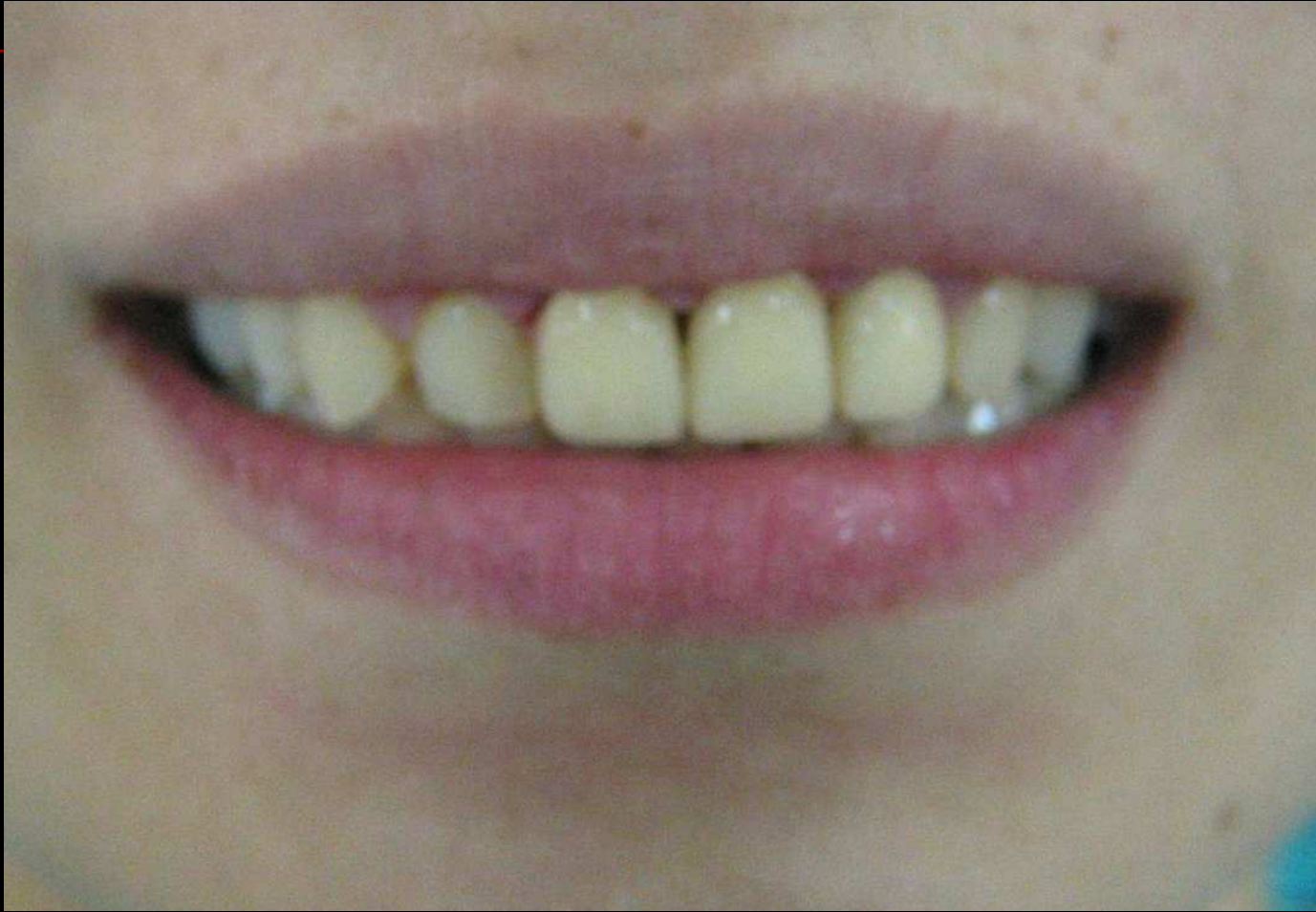


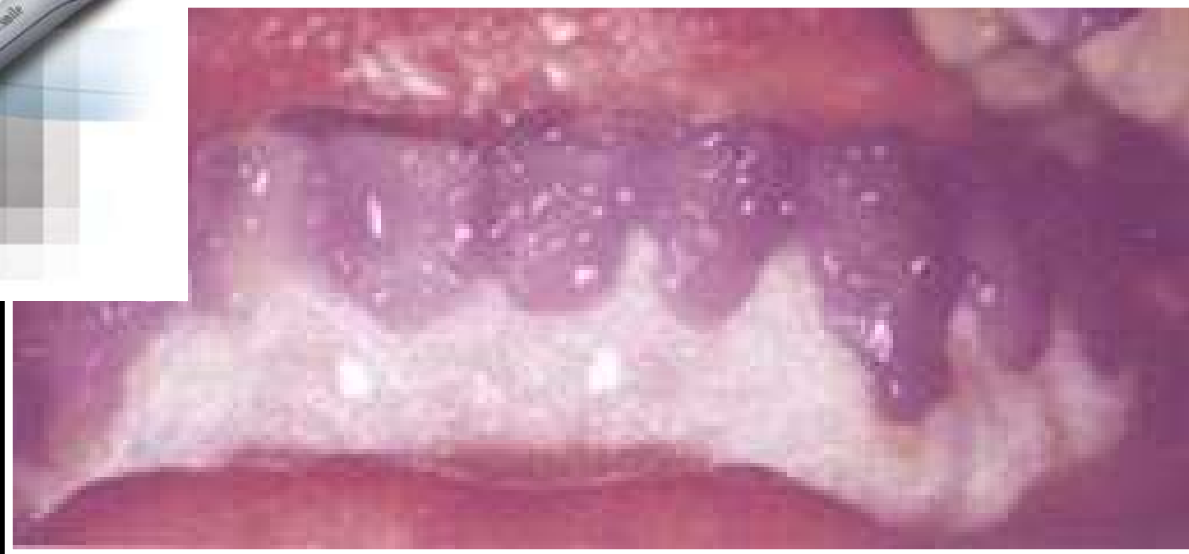1 week post-op

2 weeks post-op





---



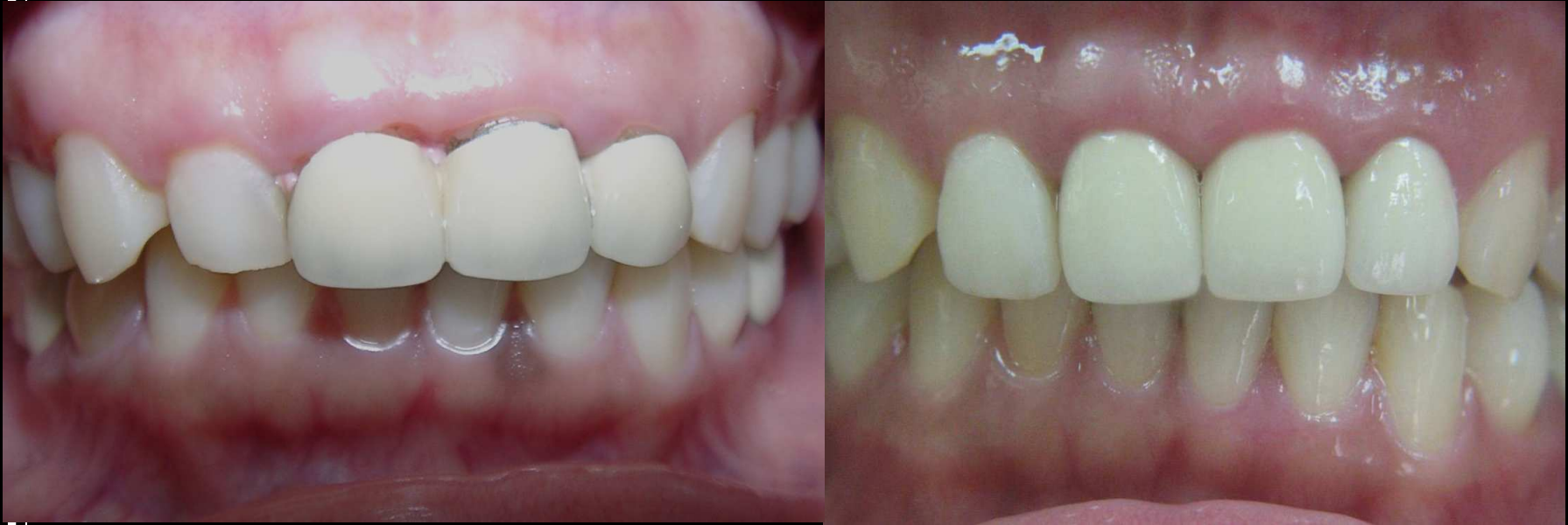7. 2002.11.15

Porcelain crowns insertion

Veneer cementation

pigment removal over gum beneath #32 with Lasersmile

---





# XI. Complication

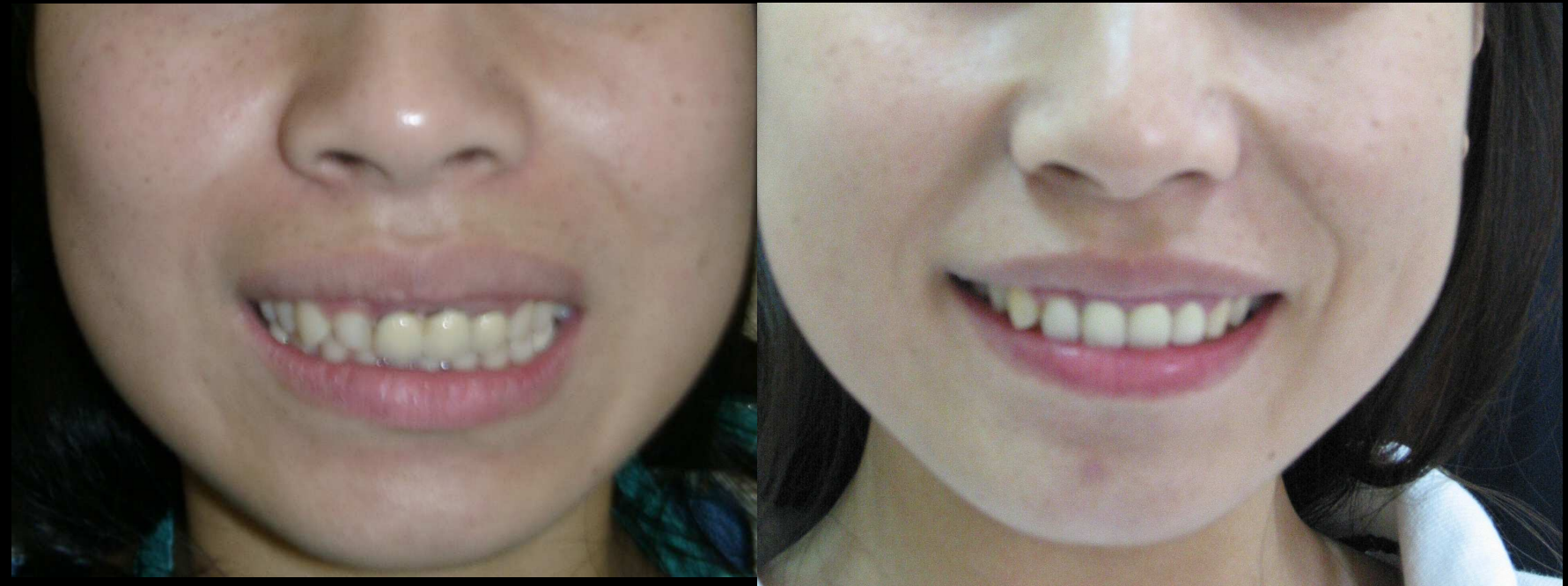
---

No

# XII. Maintenance

---

6 month follow up



# XIII. Discussion

---

Lasersmile can makes things pure.simple and predictable assuming a comprehensive diagnosis and a good communication with patient.